



PATIENT

Princess Sciarrino

SPECIES

Canine

BREED

German Shorthaired Pointer

SEX

Female Spayed

AGE

9 years

WEIGHT

47lbs

INTERPRETED BY

Maggie Machen
Lamy, DVM
DACVIM (Cardiology)

IMAGING PERFORMED BY

Pamela Harrigan,
RDCS

HOSPITAL NAME

Mass Veterinary Services

REFERRING VET

Dr. Masloski

INVOICE

22231

DATE

12/1/21

PRESENTING CLINICAL SIGNS

History: Princess is referred for a heart murmur noted in October 2018. Chest films revealed mild cardiomegaly. She had an isolated episode of heavy breathing. She is eating well with no C/S/V/D/PU/PD. Princess was on a grain free diet approximately 2 years ago. Her activity remains normal. She is in need of dental work. CV/RESP: NSR, grade IV/VI murmur with PMI left apical area radiating to right, PSS, lung fields clear. BP: 160mmHg x 2. No medications. *Sedated with propofol for study.

ECHOCARDIOGRAM FINDINGS

2D, m-mode, color flow and Doppler imaging is available.

Left ventricle: The LV diameter is normal with adequate myocardial function. LV wall thicknesses are normal.

Left atrium: The left atrium is mildly dilated.

Mitral valve: The mitral valve is mildly thickened with mild prolapse into the left atrial lumen. Mild eccentric mitral regurgitation.

Aortic valve/aorta: The aortic valve is normal in morphology and mobility. Normal aortic outflow velocity; laminar flow. No aortic insufficiency.

Right ventricle: Normal right ventricular diameter and morphology indicating no overt evidence of pulmonary arterial hypertension.

Right atrium: Normal RA dimension.

Tricuspid valve: The tricuspid valve appears mildly thickened with mild tricuspid regurgitation; normal velocity.

Pulmonic valve/pulmonary artery: The pulmonic valve is normal in morphology and mobility. No pulmonic insufficiency. Normal RVOT velocity; laminar flow.

Pericardium/other: No pericardial or pleural effusion noted. No obvious cardiac masses.

Heart rhythm: ECG reveals a sinus rhythm with an average HR of 180bpm.

2-Dimensional Measurements

Ao diam (cm)	1.9
LA diam (cm)	2.8
LA:Ao (Swe)	1.5
IVS thickness (cm)	1.0
LVID diastole (cm)	4.0
PW thickness (cm)	1.0
LVID systole (cm)	2.6
FS (%)	35

Doppler Measurements

PV Vmax (m/s)	0.82
AoV Vmax (m/s)	1.3
MR Vmax (m/s)	NM
TR Vmax (m/s)	2.5
TR PG (mmHg)	25

INTERPRETATION OF THE FINDINGS

The cause of the murmur is chronic degenerative valve disease causing mild mitral and mild tricuspid regurgitation. Lack of significant left atrial enlargement indicates the current risk for complication is low. No concurrent issues such as pulmonary hypertension are noted in this study. No evidence of diet related cardiomyopathy.

Assessment of progression in the future will help predict long term prognosis, which is highly variable at this stage (B1).



PATIENT

Princess Sciarrino

SPECIES

Canine

BREED

German Shorthaired Pointer

SEX

Female Spayed

AGE

9 years

WEIGHT

47lbs

INTERPRETED BY

Maggie Machen Lamy, DVM
DACVIM (Cardiology)

IMAGING PERFORMED BY

Pamela Harrigan, RDCS

HOSPITAL NAME

Mass Veterinary Services

REFERRING VET

Dr. Masloski

INVOICE

22231

DATE

12/1/21

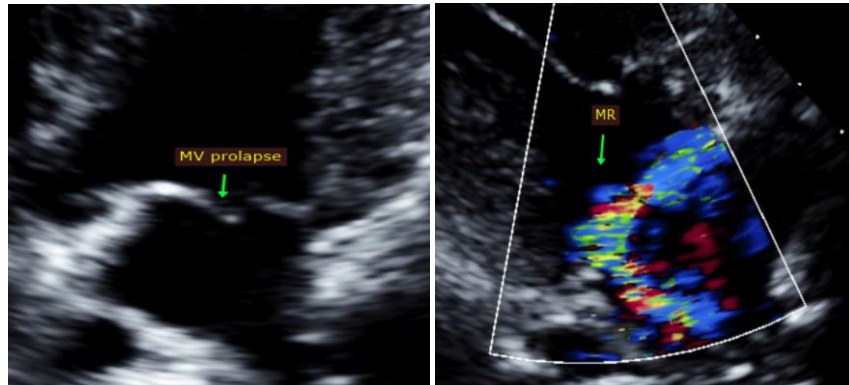
RECOMMENDATIONS

- In an asymptomatic dog without significant left atrial enlargement, no cardiac medications are clearly indicated.
- Omega fatty acid supplementation and mild salt restriction may be of some long-term benefit.
- Anesthetic risk is considered mild if needed. Cardiac protective drug choices (opioid/benzodiazepine premedication, propofol or alfaxalone induction, isoflurane gas) are recommended. Pre-oxygenate for 5-10 minutes prior to induction. Monitor for arrhythmias, hypotension, and hypoxia both intra and post-operatively and intervene as necessary. Mild IV fluid restriction is recommended to avoid fluid overload. Avoid heart rate stimulating drugs such as atropine unless clinically indicated.
- Monitor for development of a cough, labored breathing, exercise intolerance or collapse episodes.

PLAN

- Recommend conservative monitoring with a recheck echocardiogram in 6 months, sooner if any development of clinical signs.

IMAGES



The information and recommendations provided are based on the images presented by the referring veterinarian. No evaluation can be communicated regarding pathology that was not visible in the image/video clips provided.

Thank you for this referral. This report was generated using transcription software, and minor dictation errors may be present. If the clinical or image interpretation does not parallel your findings or if I can be of any further assistance, please contact me.

Maggie Machen Lamy, DVM
Diplomate of the American College of Veterinary Internal Medicine (Cardiology)
info@sonopath.com

Echocardiogram performed by: Pamela Harrigan, RDCS
Pet Animal Ultrasound Service (4paus.com)